

Thermistor Recording of Forehead Skin Temperature as an Index of Carotid Artery Disease

By MARGARET C. CONRAD, PH.D., JAMES F. TOOLE, M.D.,
AND RICHARD JANEWAY, M.D.

SUMMARY

Skin temperatures were recorded from the medial upper orbital area and above the nasal, mid and lateral portions of the brows in normal subjects and in patients with suspected cerebrovascular disease. Temperatures were reduced across the brow in patients with external carotid artery disease. Temperatures were lower than normal in the orbit in patients with internal carotid artery disease except when the internal carotid circulation was severely compromised. In such patients the supraorbital temperature was higher than normal, suggesting significant reversed flow via the supraorbital artery. With internal carotid occlusion, lateral brow temperatures suggested increases in external carotid flow. The interpretation of results was more reliable when temperatures were compared to normal values than when they were judged as differences between the two sides as is done in thermography.

Additional Indexing Words:

Cerebrovascular disease

Skin temperature of orbit

Internal carotid occlusion

Forehead temperatures

ANATOMISTS have known for years that the skin over the superomedial aspect of the forehead is supplied by terminal branches of the internal carotid artery. This knowledge was not used, however, until Heinz and associates¹ showed that when flow through the internal carotid is reduced, the temperature over this skin might be lower than that of surrounding areas. Since their initial report, there has been great interest in the perfection of methods for detecting abnormalities in internal carotid artery pressure or flow, or both, by measuring these changes directly or indirectly in this small patch of forehead skin. The question has

been, do these terminal branches reflect the condition of the internal carotid circulation within the skull and can they be used as a reliable index to monitor changes within it? The methods used to this time have included measurement of pulsations with plethysmography or temperature change by thermography, thermometers, or thermochromic paints.² There are practical and theoretical objections to the use of each of these methods. Thermography is expensive and time consuming, thermochromic paints are in the experimental state of being tested, and the use of thermometry allows the detection of temperature at only one location at a time. Consequently, we decided to adapt standard methods for measurement of temperature in the extremities to measurement of temperatures around the forehead and orbits.

Method

Beginning 15 minutes prior to the study, the subjects were placed at rest in a hospital bed in

From the Departments of Physiology and Neurology, Bowman Gray School of Medicine of Wake Forest University, Winston-Salem, North Carolina.

Work was supported by Grants HE-09525 and HENB-06655, from the U. S. Public Health Service. Dr. Conrad is an established investigator of the American Heart Association.

a laboratory maintained at 20 C (± 0.2 C). The skin surface type of thermistor probes* were attached to the forehead with transparent tape just above the medial, central, and lateral aspect of each eyebrow and at the medial upper orbital area (fig. 1). The temperatures were recorded on a strip recorder† with a temperature sensitivity of ± 0.075 C and a range of 10 to 40 C. The recorder was set to sample each point every 15 seconds. The thermistors equilibrated rapidly and the entire procedure including time for equilibration of the patient to the environment took only about 20 minutes.

Subjects

Six normal adults and 35 patients with suspected cerebral vascular disease were tested. All studies on patients were performed and interpreted without knowledge of the suspected cerebrovascular lesions. Of the 35 patients, 17 had arteriographic studies which showed bilaterally the conditions of the internal and external carotid arteries and their major branches. Arteriographic studies showed that three patients had compromised circulation to the internal and external carotids on one side only, three had occlusion of one internal carotid, two had occlusion of both internal carotids, one had occlusion of both internal carotid arteries, and stenosis of one common carotid, and four had variable compromise of internal and external carotid arteries bilaterally. In the four remaining patients with definitive bilateral arteriograms the major abnormality lay in the vertebral or subclavian arteries. These four patients were not included in this report.

*No. 400SS Thermistors, Yellow Springs Instruments Inc., Needham, Massachusetts.

†No. E1124E Esterline Angus Instrument Co., Indianapolis, Indiana.

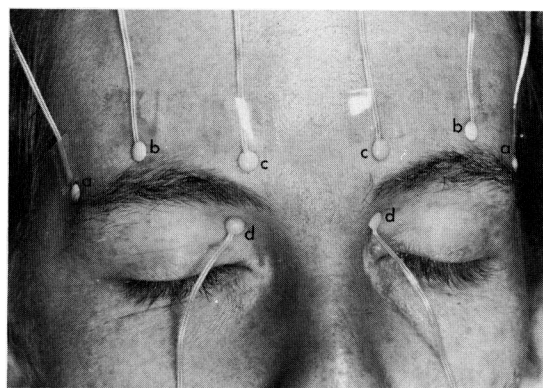


Figure 1

Placement of thermistors: a = lateral brow; b = mid brow; c = nasal brow; and d = orbit.

Circulation, Volume XXXIX, January 1969

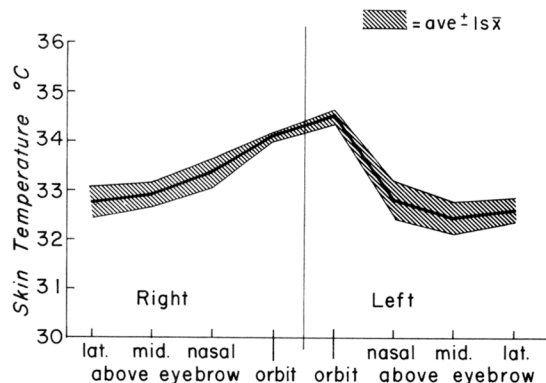


Figure 2

Normal orbital and above brow skin temperatures.

Results

Normals

In the normal individuals there was a rather consistent difference between the temperatures at comparable points on the left and right due to the pattern of air flow around the head (fig. 2). For this reason all results for patients are expressed as the difference from the normal average.

On both sides the temperatures tended to be higher above the nasal area of the brow than at more lateral areas. The temperatures

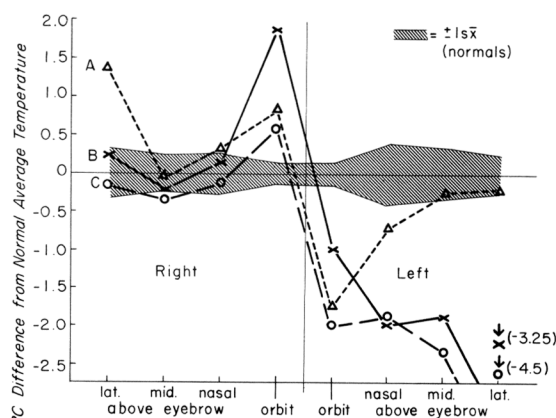


Figure 3

Orbital and above brow skin temperatures in patients with unilateral common or internal and external carotid artery disease plotted as difference from the normal average. Arteriograms show that patient A has stenosis of the left external carotid and occlusion of the left internal, patient B has severe stenosis of the left common carotid artery, and patient C has occlusion of the left common carotid.

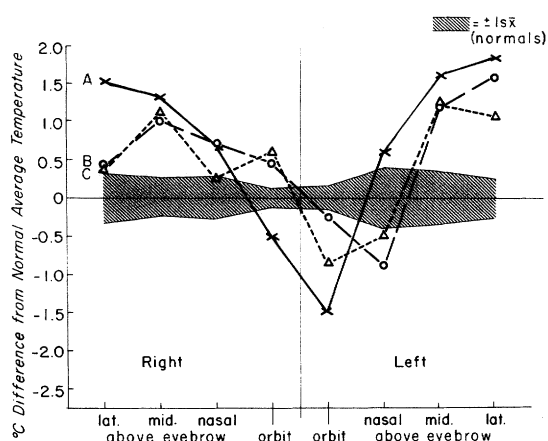


Figure 4

Orbital and above brow skin temperatures in patients with unilateral internal carotid artery disease, plotted as the difference from average normal. Patients A and B have arteriographically proven occlusion of one internal carotid artery, and patient C has stenosis of one internal carotid. The side with the occlusion is plotted to the left.

were always higher in the orbit than across the brow. Orbital temperatures varied less between subjects than the temperatures at other sites of measurement did.

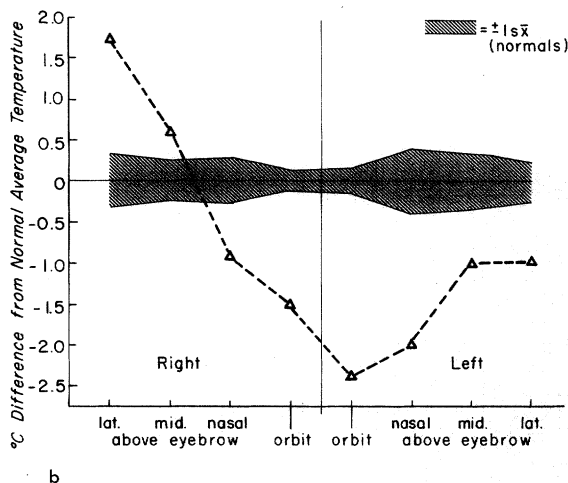
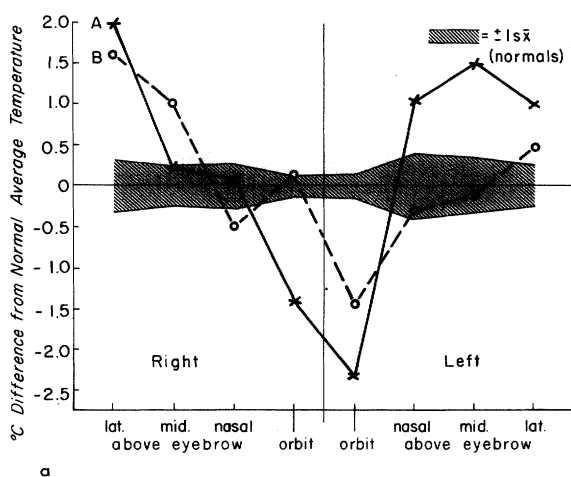


Figure 5

Orbital and above brow skin temperatures in patients with bilateral internal carotid artery disease, plotted as the difference from normal averages. (a) Arteriograms show that patient A has significant stenosis of both internal carotids and patient B has occlusion of the right with stenosis of the left and good filling of the occluded vessel via the vertebral. (b) This patient has stenosis of both internal carotids and moderate narrowing of the left carotid.

Patients with Unilateral Interference of Internal and External Carotid Flow

In these three patients, the orbital temperature on the affected side was decreased more than 1.5 C from normal and the temperature in the opposite orbit was 1 C higher than normal. The average difference between the two orbits was 2.7 C (fig. 3). The temperature across the brow on the diseased side averaged more than 1.5 C lower than normal. Patient A (fig. 3), who had occlusion of the internal carotid and stenosis of the external, had a decreased temperature at the nasal brow area, but relatively normal temperatures over the more lateral areas. Patients B and C (fig. 3), who had occlusion of the common carotid artery, had temperature drops of more than 3 C at the lateral brow area.

Patients with Unilateral Internal Carotid Artery Occlusion

This group of three patients exhibited a significant decrease in temperature in the orbit on the occluded side. There was some variability around normal in the opposite orbit and above the nasal area of the brow on the occluded side. At all other areas, temperatures were higher than normal, especially on

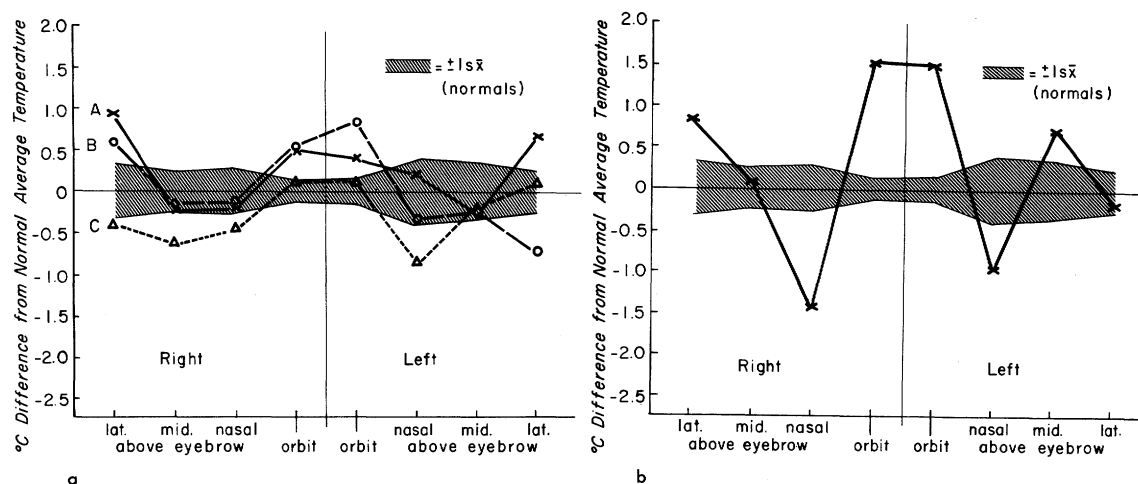


Figure 6

Skin temperatures in patients with bilaterally compromised flow in the internal and external carotids. (a) Arteriography showed that patient A had significant stenosis of both common carotids, that patient B exhibited narrowing of the right common carotid and stenosis of internal and external carotids on left, and that patient C had narrowing of both common carotids with stenosis of the left internal carotid. (b) Both internal carotids were occluded in this patient and both external arteries were stenosed. There was good filling of internal carotids via anastomoses in the eye.

the side with the internal carotid occlusion (fig. 4).

Patients with Bilateral Internal Carotid Artery Disease

In patient A (fig. 5a), who had stenosis of both internal carotids, the orbital temperatures were markedly decreased bilaterally and lateral brow temperatures were increased. Patient B (fig. 5A), who had occlusion of the internal carotid on the right side, exhibited higher orbital temperatures on the occluded side than in the opposite orbit. Interestingly, arteriographic studies in this patient demonstrated good filling of the internal carotid via the vertebral artery.

A third patient, who had stenosis of one common carotid in addition to bilateral internal carotid disease, showed decreased temperatures in both orbits, decreased brow temperatures (especially nasally) on the side with the stenosed common carotid, and higher than normal lateral brow temperatures on the opposite side (fig. 5B).

Patients with Bilateral Disease of Internal and External Carotids

As a group, the four patients with com-

promise of internal and external carotids bilaterally tended to have lower than normal temperatures in the nasal brow area and higher than normal temperatures in the orbit (fig. 6A and B).

One of the patients who had occlusion of both internals and stenosis of both external carotid arteries had markedly increased orbital temperatures. Arteriographic studies demonstrated good filling of the internal carotids via anastomosis at the eye (fig. 6B).

Discussion

When flow in both the internal and the external carotid arteries was severely compromised on the same side, the orbital and brow temperatures seemed to be diagnostic in that they indicated markedly decreased flow in branches of the internal and external carotids on the occluded side. It is of interest that the orbital temperature on the nonoccluded side in such cases suggested increased flow through the supraorbital artery. This finding illustrates the importance of observing temperatures as they vary from normal in the interpretation of results rather than

as the difference between the two sides as is done with thermography. This point is brought out even more strikingly in the finding from patients with unilateral occlusion of the internal carotid artery. The higher than normal lateral brow temperatures suggest increased external carotid flow through the superficial temporal branches especially on the side of the occlusion. If this patient had been evaluated on the basis of temperature differences between areas, one would probably have concluded that flow was decreased in branches of both internal carotids (rather than only on the occluded side) and that flow was normal in the external carotid branches.

The patient who had occlusion of one internal carotid with stenosis of the other had evidence of normal supraorbital flow on the occluded side and reduced flow on the stenosed side. This finding agreed with the thermographic pattern reported by Wood³ in such cases in which temperatures were found to be higher on the occluded than on the stenosed side. Wood attributed this to the fact that the lower pressures in the orbital vessels distal to the occlusion resulted in reversed flow through the supraorbital artery. The temperature pattern in this patient was deceptively similar to that produced by unilateral internal artery occlusion. With an essentially equal degree of internal carotid stenosis bilaterally, the temperatures followed the expected pattern indicating bilaterally decreased orbital flow and increased flow in superficial temporal branches.

With more diffuse bilateral disease the patterns usually were not markedly abnormal but were suggestive of increased collateral flow through the supraorbital vessels. When both of the internal carotid arteries were occluded and the external carotids were stenotic, temperatures as well as arteriograms indicated much more marked collateral flow via orbital vessels than when the internal carotids were only partially occluded. Comparison of temperatures with those of the normal is important in evaluation of patterns of this type

in that one could otherwise obtain the erroneous impression that only the external carotids were affected.

A higher than normal orbit temperature suggests increased flow in the supraorbital artery, but this flow could be either in the forward direction or backward from anastomoses with the superficial temporal branches toward the eye. Occlusion of one internal carotid or common carotid or stenosis of both internal carotids resulted in decreased temperatures in the affected orbits. Therefore, pressures in orbital vessels are probably not decreased sufficiently in these cases to result in significant collateral filling via the supraorbital artery. Significant reversed flow did appear to occur in the orbit in at least two instances: (1) stenosis or occlusion of both internal carotid arteries coupled with disease of the external or common carotid which resulted in increased temperatures in both orbits, and (2) occlusion of one internal carotid artery with stenosis of the other which resulted in higher temperature in the orbit on the side of the occlusion.

The results of the study indicate that abnormalities in flow in branches of the internal and of the external carotid can be demonstrated by "spot measurements" of surface temperature. The method may provide some advantage over thermography in that the equipment is much less expensive (about \$1200 versus \$20,000) and the output is in a quantitative form which can be readily compared to normal values. The comparison of values to the normal appears to aid significantly in the interpretation of results.

References

1. HEINZ, E. R., GOLDBERG, H. I., AND TAVERAS, J. M.: Experiences with thermography in neurologic patients. *Ann NY Acad Sc* **121**: 177, 1964.
2. HEYMAN, Albert: Diagnostic value of thermography in extracranial carotid occlusive disease. *In Cerebral Vascular Diseases: Fifth Princeton Conference*. New York, Grune & Stratton, Inc., 1966, p. 112.
3. WOOD, ERNEST, H.: Thermography in the diagnosis of cerebrovascular disease. *Radiology* **85**: 270, 1965.