

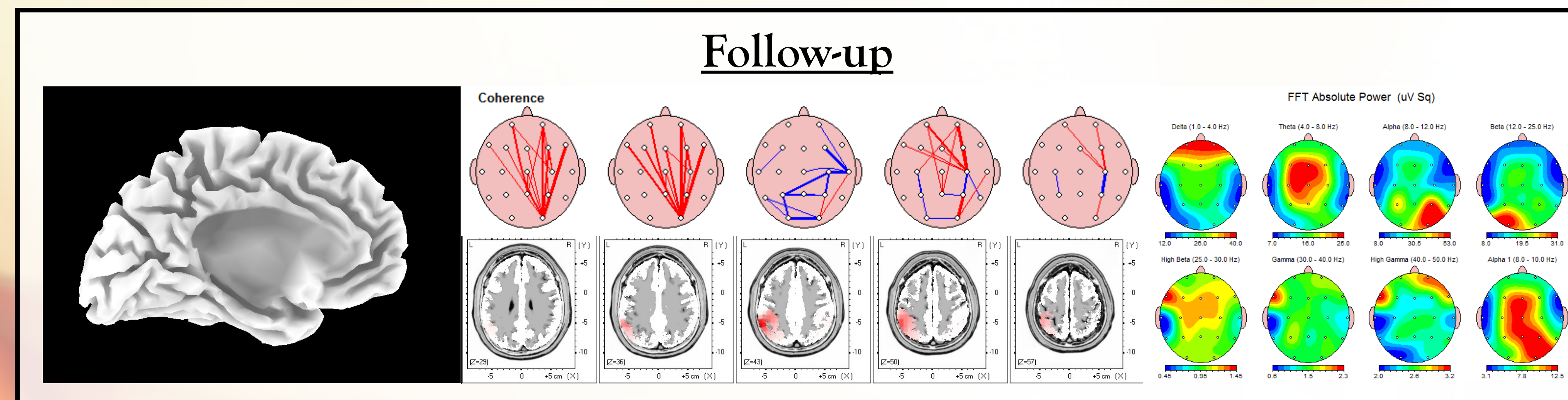
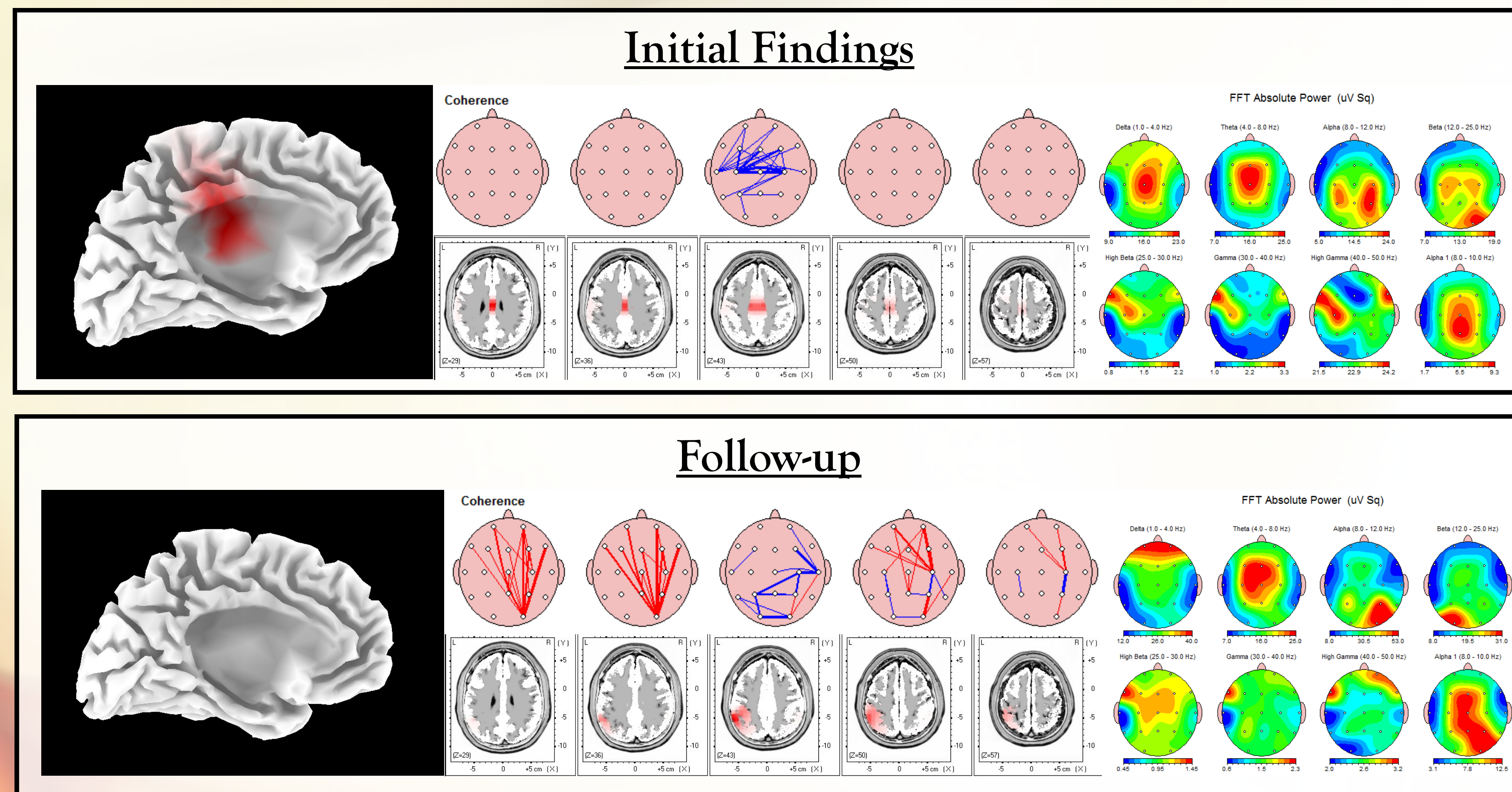
# PTSD and Seizures; A Case Study

## History.

20 year old female with Post Traumatic Stress Disorder (PTSD) following sexual assault. Presented with Seizure disorder, Sleep walking, Psychosis and previous Suicide attempt. The patient presented with seizures associated with loss of consciousness and repeated head trauma from falling, episodes of sleep walking and disturbing behaviour ranging from screaming at night to writing backwards during her sleep and escaping from home despite all exits being locked. The patient did not recall any of these events and as such were only reported by family members who have recorded some of these events. The patient also appeared to be suffering from a chronic post-concussion syndrome due to the multiple falls associated with her seizures/drop attacks. She had difficulty focusing on a conversation and would often fall asleep or yawn excessively during a conversation. Her speech was slurred and she was not able to maintain attention for substantial amounts of time.

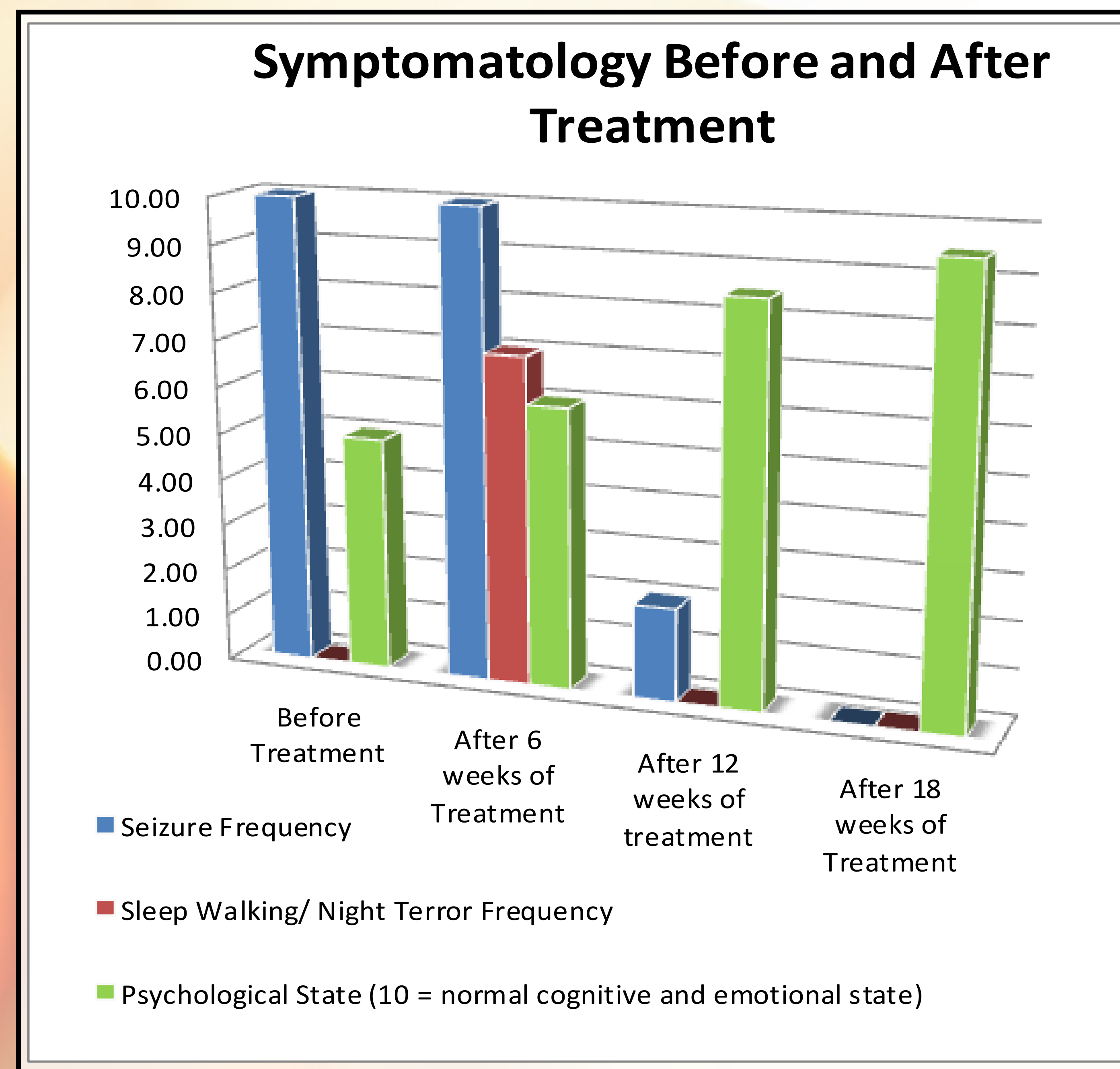
## Initial Finding

Upon initial assessment and quantitative electroencephalography (qEEG) hypoactive coherence was noted. When looking at the individual frequency ranges, there was a generalised hypoactivity in the frontal, parietal and occipital lobes bilaterally. These are consistent throughout the delta, theta, alpha, beta, high beta and gamma frequency ranges. There is also an area of hyperactivity in the cingulate gyrus noted in the delta, theta and alpha frequencies. The LORETA analysis showed that the most significant dysfunction was in Brodmann areas 23 and 24. These form part of the limbic association cortex and are mostly associated with emotion.



## Follow up Findings

The follow up Quantitative electroencephalographic (qEEG) examination demonstrated a normalization in the hypoactive coherence. When looking at the individual frequency ranges, there was a generalised normalization of hypoactivity in the frontal, parietal and occipital lobes bilaterally. The area of hyperactivity in the cingulate gyrus is no longer present in the delta frequency. LORETA analysis showed that the areas of dysfunction (Brodmann areas 23 and 24) were completely normalized and no dysfunction was present.



## Conclusion

After 6 months of therapy, the patient's qEEG is much improved in appearance showing normalization of most hypoactive areas throughout all frequency ranges as well as a decrease in the areas of hyperactivity. LORETA analysis shows complete resolution of the primary dysfunctional area. The patient was asked to record a headache diary which measured frequency and intensity of each headache episode. When comparing the data initially against follow-up there was a significant improvement in both areas. There was a reduction in frequency by 77% (99% to 22%) and intensity reduced by 38% (79% to 41%). Symptomatically, the patient has seen significant improvement in her general condition. She has been seizure free for 14 weeks and her sleep walking episodes have drastically decreased in frequency. The patient no longer slurs her speech and is able to maintain focus throughout a conversation without yawning or feeling fatigued.